Combination of ION Robotic Bronchoscopy with Body Vision C-Arm Based Tomography for Optimal Lesion Localization and Sampling

Gene Cho[1], Moreen Matti[1], Victoria Nobari[2], George Cheng[3], Russell Miller[3], Matthew Nobari[3]. [1]University of California San Diego (UCSD), La Jolla, CA, United States. [2]Marian University - College of Osteopathic Medicine, Indianapolis, IN, United States. [3]Division of Pulmonary, Critical Care, and Sleep Medicine, University of California San Diego (UCSD), La Jolla, CA, United States

Introduction

•Body Vision utilizes real time, intraoperative C-Arm Based Tomography (CABT) imaging to provide excellent lesion localization and confirmation

•ION's (Intuitive Surgical) robotic catheter allows for minimal deflection and increased stability to allow for accurate navigation to lesions

•The combination of Body Vision and ION was vital for optimal lesion localization and sampling in this case

Case

• 61 year old female with history of COPD and tobacco use presented with inferior lingular nodule

•Navigational bronchoscopy was initially performed, yet rapid on-site evaluation (ROSE) cytology showed inconclusive pathology

•Transthoracic Needle Aspiration (TTNA) was performed subsequently, also leading to inconclusive pathology

•Lastly, ION in conjunction with Body Vision CABT augmented fluoroscopy allowed for navigation to peripheral lesion through ION's robotic catheter, along with real-time intraoperative confirmation of lesion location and tool in lesion confirmation

•Sampling was performed with positive ROSE by cytology, with final pathology positive for carcinoid

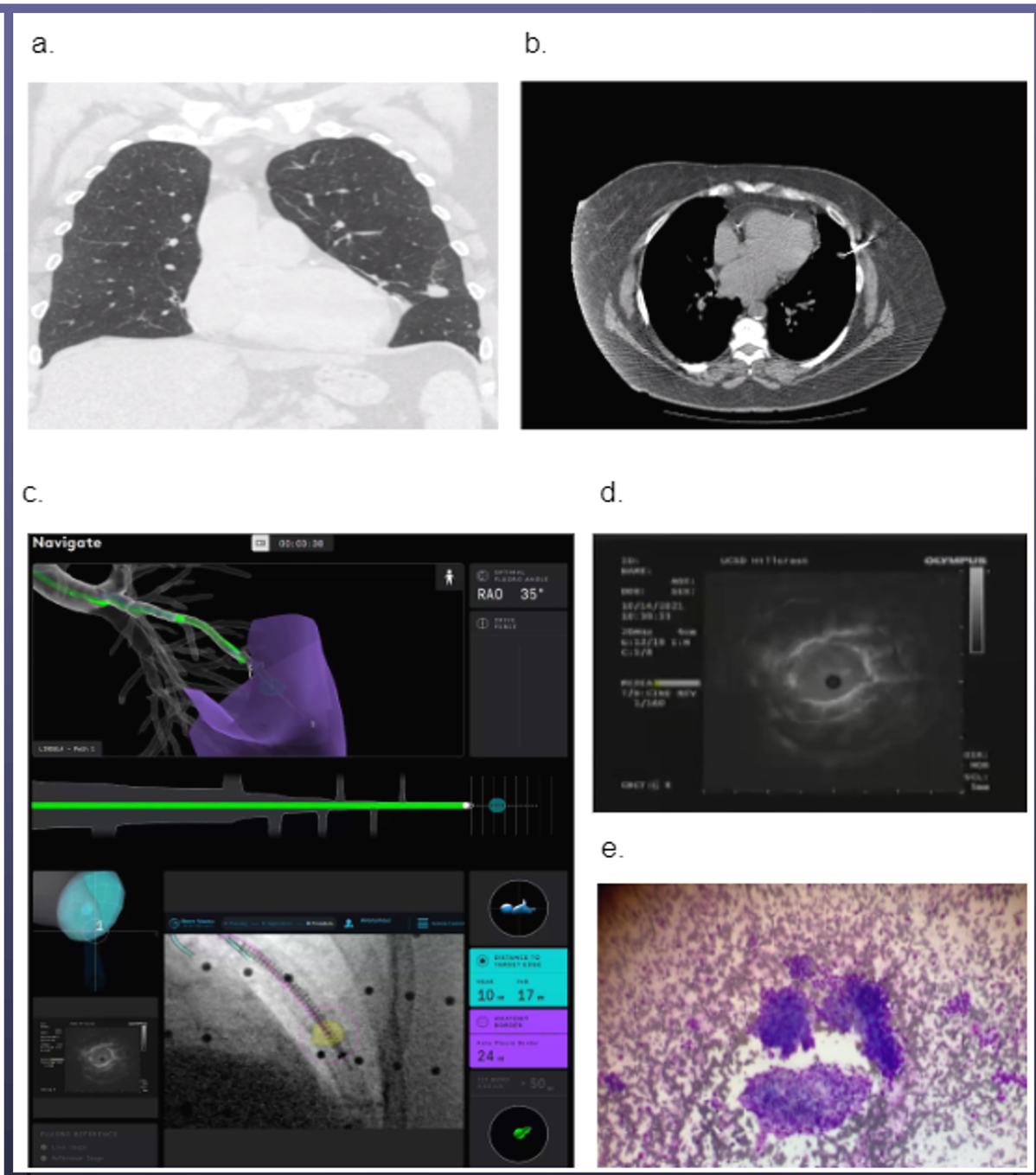

Figure 1: a. Coronal chest CT scan of lingular nodule. **b.** IR-guided transthoracic needle biopsy. c. Robotic Bronchoscopy Pathway and BodyVision augmented fluoroscopic images. **d.** Radial EBUS image demonstrates concentric lesion. **e.** Positive cytology on rapid-on site evaluation.

Discussion

• Patient previously went through navigational bronchoscopy and TTNA, both providing inconclusive results

•The combination of Body Vision's localization technology along with ION's robotic catheter allowed for an accurate navigation to the lesion effectively

•Body Vision's localization and ION's navigation allowed for completion of robotic bronchoscopy in only 23 minutes, highlighting the synergy and optimization with the two technologies combined

Conclusion

• Use of BodyVision and ION robotic bronchoscopy in conjunction resulted in a procedure finished in a safe and timely manner

•The combination technology is particularly useful in cases involving small peripheral lesions due to the ability to accurately localize the lesion and confirm tool in lesion

Reference

1. Sung, H, Ferlay, J, Siegel, RL, Laversanne, M, Soerjomataram, I, Jemal, A, Bray, F. Global cancer statistics 2020: GLOBOCAN estimates of incidence and mortality worldwide for 36 cancers in 185 countries. *CA Cancer J Clin*. 2021: 71: 209- 249. https://doi.org/10.3322/caac.21660
2. Ellis, P. M., & Vandermeer, R. (2011). Delays in the diagnosis of lung cancer. *Journal of thoracic disease*, *3*(3), 183–188. https://doi.org/10.3978/j.issn.2072-1439.2011.01.01
3. Agrawal, A., Hogarth, D. K., & Murgu, S. (2020). Robotic bronchoscopy for pulmonary lesions: a review of existing technologies and clinical data. Journal of thoracic disease, 12(6), 3279–3286. https://doi.org/10.21037/jtd.2020.03.35
4. Jiang, J., Chang, S. H., Kent, A. J., Geraci, T. C., & Cerfolio, R. J. (2020). Current Novel Advances in Bronchoscopy. *Frontiers in surgery*, *7*, 596925. https://doi.org/10.3389/fsurg.2020.596925